

REVIEW

Adjuvant therapy in adrenocortical carcinoma: prognostic factors and treatment options

Ruaa Al-Ward^{1,2}, Celeste Zsembery³ and Mouhammed Amir Habra¹

¹Department of Endocrine Neoplasia and Hormonal Disorders, The University of Texas MD Anderson Cancer Center, Houston, Texas, USA

²Department of Endocrinology, Diabetes and Metabolism, Baylor College of Medicine, Houston, Texas, USA

³Departments of Medicine and Pediatrics, Baylor College of Medicine, Houston, Texas, USA

Correspondence should be addressed to M A Habra: mahabra@mdanderson.org

Abstract

Adrenocortical carcinoma (ACC) is a rare cancer with high recurrence rates and heterogeneous clinical behavior. The role of adjuvant therapy remains unclear because of the challenges in collecting high-quality data for a rare cancer. The current treatment recommendations and guidelines for adjuvant therapy are mostly derived retrospectively from national databases and the treatment outcomes of patients seen in referral centers. To better select patients for adjuvant therapy, multiple factors need to be considered including staging, markers of cellular proliferation (such as Ki67%), resection margins, hormonal function, and possibly genetic alterations of the tumor as well as patient-related factors such as age and performance status. Adjuvant mitotane remains the most commonly used adjuvant therapy in ACC based on clinical practice guidelines, though emerging data from ADIUVO trial (mitotane vs observation in low-risk ACC) suggest that mitotane use in low-risk patients may not be needed. An ongoing clinical trial (ADIUVO-2) is evaluating the role of mitotane vs mitotane combined with chemotherapy in high-risk ACC. The use of adjuvant therapy has been controversial but can be justified in select patients with positive resection margins or after the resection of localized recurrence. A prospective study is needed to study the role of adjuvant radiation in ACC as radiation is expected to help only with local control without impact on distant microscopic metastases. There are no recommendations or published data about using adjuvant immunotherapy in ACC, but this may be a future study after establishing the efficacy and safety profile of immunotherapy in metastatic ACC.

Key Words

- ▶ adrenocortical carcinoma
- ▶ adjuvant therapy
- ▶ mitotane
- ▶ chemotherapy
- ▶ radiation therapy

Endocrine Oncology
(2022) 2, R90–R101

Introduction

Adrenocortical carcinoma (ACC) is a rare aggressive malignant tumor with a poor prognosis despite its well-known heterogeneous behavior. It was first described in a case series by Ramsay (1899). Despite the improvements in diagnostic imaging and the recognition of ACC over the last century, its annual incidence in adult patients has remained relatively stable which is estimated to be around 0.7–2 cases per million people (Kerkhofs *et al.* 2013).

ACC has a bimodal age distribution with a small peak before the age of 5 years, primarily for *TP53* gene mutations (~50–80% of pediatric cases) and a larger peak in patients 40–60 years old (Else *et al.* 2014a). Most ACC cases are sporadic, with a few linked to genetic syndromes such as Li-Fraumeni syndrome, Lynch syndrome, Carney complex, and multiple endocrine neoplasia type 1 syndrome. ACC is recognized more commonly in

female patients (1.5–2.5:1) compared to male patients (Jasim & Habra 2019).

Over the past few decades, improvements in surgical techniques and postoperative care for patients with ACC have made surgery the crucial initial step in ACC management (Grubbs *et al.* 2010). However, despite surgeons' best efforts, ACC has a recurrence rate as high as 30–70% (Ayala-Ramirez *et al.* 2013, Glenn *et al.* 2019, Turco *et al.* 2021) and is associated with substantial decreases in life expectancy and a poor 5-year overall survival (OS) rate ranging between 0% and 45% (Margonis *et al.* 2016a, Tran *et al.* 2016). Thus, effective adjuvant therapy is critically needed to improve the prognosis in adult patients with ACC.

Adjuvant therapy, including chemotherapy, immunotherapy, hormonal therapy, and radiotherapy, has been widely used in many cancers such as prostate cancer and breast carcinoma among others (Bolla *et al.* 2012, Masuda *et al.* 2017).

Over the past few decades, multiple reports were published about the optimal post-surgical therapies to decrease ACC recurrences but only two clinical trials (ADIUVO and ADIUVO-2 trials) have been launched to prospectively validate the published retrospective data (Terzolo *et al.* 2021) (ClinicalTrials.gov identifier: NCT03583710). These therapies include mitotane, the first antineoplastic drug used for patients with advanced ACC; radiation therapy (RT); chemotherapy, etoposide, doxorubicin, cisplatin, streptozocin, and gemcitabine widely used in retrospective studies; and, more recently, immunotherapy and targeted molecular therapy.

In this review, we summarized the published experience regarding adjuvant therapy in ACC and prognostic factors. In addition, we provided detailed descriptions of the use of RT, mitotane, and cytotoxic chemotherapy in these patients based on the current status of literature. We also discussed the potential use of immunotherapy in ACC and provided recommendations regarding the choice of therapy based on the risk factors associated with ACC prognosis.

Prognostic factors in localized ACC

Surgical resection by an expert surgeon is the most important first step in the management of ACC. While it is hard to assess the level of surgical expertise, it is highly recommended to refer those patients to centers known for their experience in ACC management to ensure the highest level of possible care.

After resection, given the rarity of ACC and the absence of prospective studies, multiple prognostic factors can be used to predict the risk of disease recurrence and justify the use of adjuvant therapy. These factors include the patient's disease stage, surgical margins, cell proliferation markers, hormonal status, age, genetic profile, and the surgical approach used.

Stage

ACC staging is an independent predictor of disease recurrence. In a 2009 study from the German ACC registry including 416 ACC patients, the 5-year disease-specific survival rate was 82% for patients with stage I, 58% for stage II, 55% for stage III, and 18% for stage IV ACC patients (Fassnacht *et al.* 2009). Additionally, a 2013 study of 330 patients at the University of Texas MD Anderson Cancer Center showed that disease-specific survival depends on the disease stage. Patients' median overall survival (OS) duration was 24.1 years for stage I, 6.1 years for stage II, 3.5 years for stage III, and 0.9 years for stage IV ACC (Ayala-Ramirez *et al.* 2013).

Using tumor size, extension, regional lymph node involvement, and the evaluation of distant metastasis (tumor, node, metastasis (TNM) classification) are the key elements in ACC staging (Jasim & Habra 2019). The TNM classification of ACC was first proposed in 2004 by the International Union Against Cancer and the American Joint Committee on Cancer. Later, the 2008 European Network for the Study of Adrenal Tumors (ENSAT) staging system reclassified stage III tumors as all locally advanced tumors and stage IV tumors as only those with distant metastases at the time of the initial diagnosis (Fassnacht *et al.* 2009). This staging system considering stage IV only in patients with distant metastases was also recently adopted by the American Joint Committee on Cancer Eighth edition (Amin *et al.* 2017).

Surgical margins

Positive surgical margins are associated with high recurrence rates in many cancers, including common malignancies such as prostate and breast cancers (Heiss *et al.* 2017, Zhang *et al.* 2018). Positive surgical margins (R1 resection) are a risk factor for worse outcomes in ACC and are associated with shorter OS and recurrence-free survival (RFS) compared to patients with negative margins (R0 resection) (Ayala-Ramirez *et al.* 2013, Nowak *et al.* 2018). Data from the National Cancer Database from 1985 to 2005 showed that the rate of margin-positive resection

is high, around 19% (Bilimoria *et al.* 2008). Additionally, a German study suggested that the OS of patients with positive margins (R1) stage II disease is similar to or worse than that of patients with completely resected (R0) stage III disease (Fassnacht *et al.* 2009).

From 13 tertiary academic centers in the United States, the 5-year RFS rate in univariate analysis was higher among patients with R0 resection than among patients with R1 resection (30.3% vs 13.8%, respectively; HR, 1.71; 95% CI, 1.05–2.78; $P = .03$) (Margonis *et al.* 2016b). Another study of 330 patients from a single center confirmed this finding (Ayala-Ramirez *et al.* 2013). However, in both studies, this finding becomes statistically insignificant in the multivariate analysis and neither study could confirm surgical margins as independent predictors of RFS. This is likely because both studies were underpowered to detect the effect of margin status on RFS.

In 2018, a National Cancer Database meta-analysis of 1553 patients with ACC found that those with negative margins (R0) had a significantly longer median survival duration (57.6 months; 95% CI, 48.5–66.0) than those with positive margins both microscopically (22.4 months; 95% CI, 17.6–33.5) with hazards ratio (HR) of 1.76 (95% CI, 1.37–2.26; $P < 0.001$) and macroscopically (13.7 months; 95% CI, 5.8–26.8) with HR of 2.10 (95% CI, 1.21–3.65; $P = 0.009$) (Anderson *et al.* 2018).

Current guidelines do not have specific recommendations for adjuvant therapy in patients with stage I–II ACC with R0 resection and Ki67 percentage scores less than or equal to 10%, but they highly recommend adjuvant therapy for patients with positive surgical margins (Fassnacht *et al.* 2018).

Cell proliferation markers

Ki67 proliferation index is among the most powerful prognostic molecular marker in ACC. The largest study, from 2015, looked at 319 German patients and 240 patients from 3 other European countries showed that the HR of the RFS increased sequentially with the Ki67 index, with 10% and 20% percentage scores correlating to HRs of 1.94 ($P = 0.0034$) and 2.58 ($P = 0.001$), respectively (Beuschlein *et al.* 2015). The median OS also correlated with the Ki67 index. Ki67 percentage scores of less than 10%, of 10–19%, and $\geq 20\%$ or greater were associated with median OSs of 180.5 months, 113.5 months, and 42 months, respectively. Ki67 has also been validated in the pediatric ACC population, where it reliably predicts worse outcomes (Martins-Filho *et al.* 2021, Riedmeier *et al.* 2021). A study that included 146 adult patients and 44 pediatric patients

with ACC showed that an increase of even 1% in the Ki67 index could have a significant impact on OS and disease-free survival (DFS) ($P < .001$) (Martins-Filho *et al.* 2021).

The mitotic rate of the tumor cells has been also associated with poor outcomes. A 2010 study by the University of Michigan found significantly worse outcomes (time to recurrence, $P = 0.011$; time to death, $P = .004$) in patients whose tumor cells had a high (20 mitoses per 50 high-power fields) rate of mitosis compared with a low (12 mitoses per 50 high-power fields) rate of mitosis (Miller *et al.* 2010). However, Ki67 index was found to be superior to mitotic index in predicting OS (Duregon *et al.* 2014). Currently, the ENSAT guidelines recommend all patients should have pathological staging using the Weiss system, which includes mitotic rates as part of its criteria (Fassnacht *et al.* 2018). Thus, the Ki67 index and Weiss scores are important components in pathological disease staging.

Hormonal status

Hormonally functional ACCs have been reported in 50–75% of cases (Else *et al.* 2014b), and multiple studies have shown that hormonally functional status is a predictor of poor prognosis. A meta-analysis of 19 studies, including a cohort study of 3814 patients with different stages of ACC, found that the mortality relative risk was 1.54 in hormonally functional tumors compared with hormonally nonfunctional tumors in data from models adjusting for tumor stage (95% CI, 1.28–1.85) and 1.71 in cortisol-secreting tumors compared with non-cortisol-secreting tumors (95% CI, 1.18–2.47) (Vanbrabant *et al.* 2018). Additionally, a recent study of 62 patients with ACC done by the National Cancer Institute and Memorial Sloan Kettering Cancer Center found that 78% of the 18 patients who had OS less than 12 months had hormonally functional tumors, whereas only 48% of those who survived more than 24 months had hormonally functioning tumors (Ayabe *et al.* 2020).

Of all the types of hormonally active tumors, glucocorticoid tumors have the poorest prognosis, which is likely due to their immunosuppressive nature and considerable systemic impacts. In a recent study of 164 tumor samples from patients with ACC, it was found that the presence of a high number of tumor-infiltrating T cells (TILs), including T helper, cytotoxic T, and regulatory T cells, was associated with better survival (HR for death, 0.47; 95% CI, 0.25–0.87), but the presence of TILs was negatively impacted by excess glucocorticoids ($\phi = -0.290$; $P = 0.009$) (Landwehr *et al.* 2020). The study concluded that patients with excess glucocorticoids and

low numbers of TILs had a particularly poor median OS of 27 months, whereas those with sufficient numbers of TILs and no excess glucocorticoids had a median OS of 121 months (Landwehr *et al.* 2020).

Age

ACC can affect any age group, although it most typically affects patients in their 50s to 60s and patients younger than 5 years old if they have a genetic predisposition. Age is an independent prognostic factor; older adults usually have a poorer prognosis. This is likely multifactorial related to increase in comorbidities and reduced tolerance to systemic therapy. It is unknown if age by itself is associated with a more aggressive tumor. A 2014 study of 391 ACC patients showed that age at the time of diagnosis was inversely related to OS (HR, 1.01; $P=0.018$) (Else *et al.* 2014b). Another study of 330 patients with ACC in a tertiary care center found that increased age at the time of the diagnosis had an HR of 1.003 (95% CI, 1.003–1.024; $P=.0089$) (Ayala-Ramirez *et al.* 2013). Similarly, a cohort study of 66 patients found that having an age older than 50 was an independent variable associated with decreased OS (HR, 1.09; $P=.001$) (Nowak *et al.* 2018). The 5-year survival rate for patients less than 50 years old was 66.9% (95% CI, 44.2–82.1), which is much better than patients older than 50 years 29.3% (95% CI, 14.1–46.3) ($P=0.004$).

Genetic profile

Although most ACCs develop sporadically, a minority of cases are seen in the context of familial cancer syndromes, including Li-Fraumeni syndrome, Beckwith-Wiedemann syndrome, Carney complex, and multiple endocrine neoplasia type 1 (Angelousi *et al.* 2016). As ACC can be the initial presentation of these familial syndromes, it is important to consider further genetic workup.

In 2016, The Cancer Genome Atlas pioneered the first comprehensive, integrated genomic characterization study of 91 patients who were from six different countries and who had histologically confirmed ACC group.

This study analyzed ACC's clinical and pathologic features, genomic alterations, DNA methylation profiles, and RNA and proteomic signatures, providing a worldwide perspective into the critical alterations responsible for ACC tumorigenesis and progression. The most frequent genetic alterations discovered were *P53*, *ZNRF3*, *CDKN2A*, *CTNNB1*, *TERT*, and *PRKARIA*. Consensus clustering analyses were created based on alteration in DNA copy number, DNA methylation, mRNA expression, and

micro RNA expression, which resulted in three molecular classification subtypes with different outcomes (Zheng *et al.* 2016). The disease progression rates were 7%, 56%, and 96% for the cluster of cluster subtypes I, II, and III, respectively. In addition, the cluster of cluster subsets II and III were found more frequently in stage III/IV tumors (47% and 52%, respectively) than were a cluster of cluster subset I (25%) (Zheng *et al.* 2016). Additionally, disease aggressiveness was identified by the whole-genome doubling.

In 2019, a prognostic study of 368 patients who underwent surgical removal of localized ACC found that molecular classification was an independent prognostic factor for OS and DFS (Assié *et al.* 2019). In this study, three discrete molecular classes – A1, A2, and A3 to B – were created based on the ENSAT guidelines and The Cancer Genome Atlas molecular classes of ACC. The 5-year OS rate was 9% for the A1 group, 45% for the A2 group, and 82% for the A3 to B group ($P < 0.001$). The HR for disease-related survival was 55.91 for group A1 compared with group A3 to B 95% CI, 8.55–365.40; $P < 0.001$).

Specific microarray gene markers, such as the differential gene expression of *BUB1B/PINK1*, improve the diagnosis and the prognostic assessment of ACC. ACC is predicted to have a poor prognosis and fatal outcome if the molecular predictor (*DLGAP5-PINK1*) is ≤ 3.22 (Fragoso *et al.* 2012). Similarly, *G0S2* hypermethylation and silencing causing upregulation of cell cycle is the hallmark of rapidly recurrent or fatal ACC as it independently predicts shorter DFS and OS (Mohan *et al.* 2019).

Another analysis showed that overexpression of *VAV2*, which is a steroidogenic factor-1 dosage-dependent target, was an independent prognostic factor for shorter PFS and OS in a multivariate analysis (Sbiera *et al.* 2017). Furthermore, *Ki67* and *VAV2* expression were significantly correlated and could be used to stratify patients into high-risk and low-risk groups. These studies suggest that a patient's genetic profile has a significant impact on prognosis and should be used in conjunction with other predictors. So far, there is no published data that correlates adjuvant therapy outcomes with underlying genetic alterations. Future studies can include an exploratory objective to study the correlation between select molecular factors and responses to adjuvant therapy.

Surgical approach

For many cancers, laparoscopic approaches are often favored, compared to open surgeries, because they are associated with shorter operative time, less blood loss,

and shorter hospital stays. However, in ACC, laparoscopic resection has been linked to inferior outcomes and high rates of positive resection margins. A study of 256 patients with ACC showed that, among patients who underwent laparoscopic rather than open surgery, there was a higher rate of positive resection margins (R1 or R2) (28.3% vs 17.6%; $P=0.01$) and a shorter median OS (10.9 months vs 19.6 months; $P=0.005$) (Cooper *et al.* 2013). Similarly, a Chinese study of 42 patients showed that the mean DFS for patients who underwent open vs laparoscopic adrenalectomy was 44.8 ± 35 months and 17.5 ± 10.4 months, respectively ($P=0.023$) (Zheng *et al.* 2018). The presumed reasons for the high rates of treatment failure after laparoscopic surgery are the higher rates of positive margin resections and the seeding of the laparoscopic tract with tumor cells, although this is debated in the literature. There are no randomized, controlled studies evaluating laparoscopic vs open adrenalectomies.

Meta-analyses of the literature have shown controversial outcomes when the laparoscopic and open surgical approaches were compared. Agourakis *et al.*'s meta-analysis of 4 studies with a total of 253 patients showed favorable 5-year survival in patients who underwent open vs laparoscopic adrenalectomy ($P=0.4$) (Sgourakis *et al.* 2015), but 3 other meta-analyses showed no statistically significant differences between the 2 approaches in terms of recurrence rate and mortality. These studies include Mpaili *et al.*'s meta-analysis of 13 studies of 1171 patients, Autorino *et al.*'s analysis of 9 studies of 797 patients, and Langenhuijzen *et al.*'s analysis of 26 publications (Autorino *et al.* 2016, Langenhuijzen *et al.* 2016, Mpaili *et al.* 2018). However, all of these studies were observational, and some of them have partially reported oncological outcomes.

Therefore, open surgery remains the standard goal in ACC surgeries, especially for suspected ACC >6 cm. Laparoscopic resection can be considered on a case-by-case basis when an experienced surgeon is available and presuming the adrenal mass is <6 cm without any signs of local invasion or lymphadenopathy (Fassnacht *et al.* 2018, Liang *et al.* 2020).

Prognostic calculators

Several calculators were created to provide guidance for the best postoperative treatment course. However, neither has been the optimal tool for prognostication established yet or has been validated prospectively. Helsinki score was created in 2015 to provide a prognostic indicator based on the combination of the morphology (mitoses and necrosis) and immunohistochemical (Ki-67) parameters (Pennanen

et al. 2015). This score consists of a $3 \times$ mitotic rate ($>5/50$ high-power fields) + $5 \times$ presence of necrosis + proliferation index in the most proliferative area of the tumor. Patients with a score of 0–8.5 had OS of 100% at 2 years, while patients with a score of 8.5–17 (>17) had OS of 70% and 20%, respectively ($P=0.010$) (Pennanen *et al.* 2015).

Another prognostic score was suggested in the same year using a composite score of (Ki67 index, tumor size, and presence of tumor venous thrombus) (Beuschlein *et al.* 2015). This score was able to discriminate the German ACC cohort registry of 319 patients into groups with different clinical outcomes and can be used to predict outcomes but not select adjuvant therapy.

Most recently, modified S-GRAS (stage, grade, resection status, age, symptoms) was validated in a large, multicenter retrospective study of 942 ACC patients (Elhassan *et al.* 2021). The updated score generated four S-GRAS groups 0–1, 2–3, 4–5, and 6–9 depending on five factors which include modified ENSAT stages I–III (1–2=0; 3=1; 4=2), grade (Ki67 index 0–9%=0; 10–19%=1; $\geq 20\%=2$ points), resection status (R0=0; RX=1; R1=2; R2=3), age (<50 years=0; ≥ 50 years=1), and symptoms (no=0; yes=1). The higher the S-GRAS scores, the higher risk of disease progression. Comparing S-GRAS 0–1, patients with S-GRAS 2–3, 4–5, and 6–9 had, respectively, 2.8, 6.4, and 11.5 times ($P < 0.0001$) higher risk of disease progression. This system showed better performance compared to the ENSAT staging and KI 67%.

Types of adjuvant therapy in adrenocortical carcinoma

Radiation therapy

In 1896, Wilhelm Roentgen discovered the X-ray. Three months later, the X-ray was used for the diagnosis of different diseases, and 3 years later, RT was used for skin cancer treatment. In 1932, the ionizing radiation chamber was introduced, helping physicians with radiation dose measurements (Thoraeus 1932). Over the subsequent 90 years, phenomenal leaps forward in technology have honed RT to very delicate, precise treatments for a variety of solid tumors.

Adjuvant RT is widely used in different malignancies to prevent tumor recurrence. For example, it is commonly used as an adjuvant treatment for common malignancies such as breast cancer and prostate cancer. In breast cancer patients, it is estimated that the number needed to treat with adjuvant RT is 6.3 patients to add 1 survivor at 10 years (Early Breast Cancer Trialists' Collaborative Group 2011). Similarly, the use of adjuvant RT for prostate cancer

significantly improved the 10-year, metastasis-free survival with a median of 14.7 years (HR, 0.75; 95% CI, 0.55–1.02; $P=0.16$) (Thompson *et al.* 2006). Despite the favorable outcome of using adjuvant RT in many types of cancer, data regarding the efficacy of using adjuvant RT in ACC is conflicting; thus, RT is used less often to treat patients with ACC.

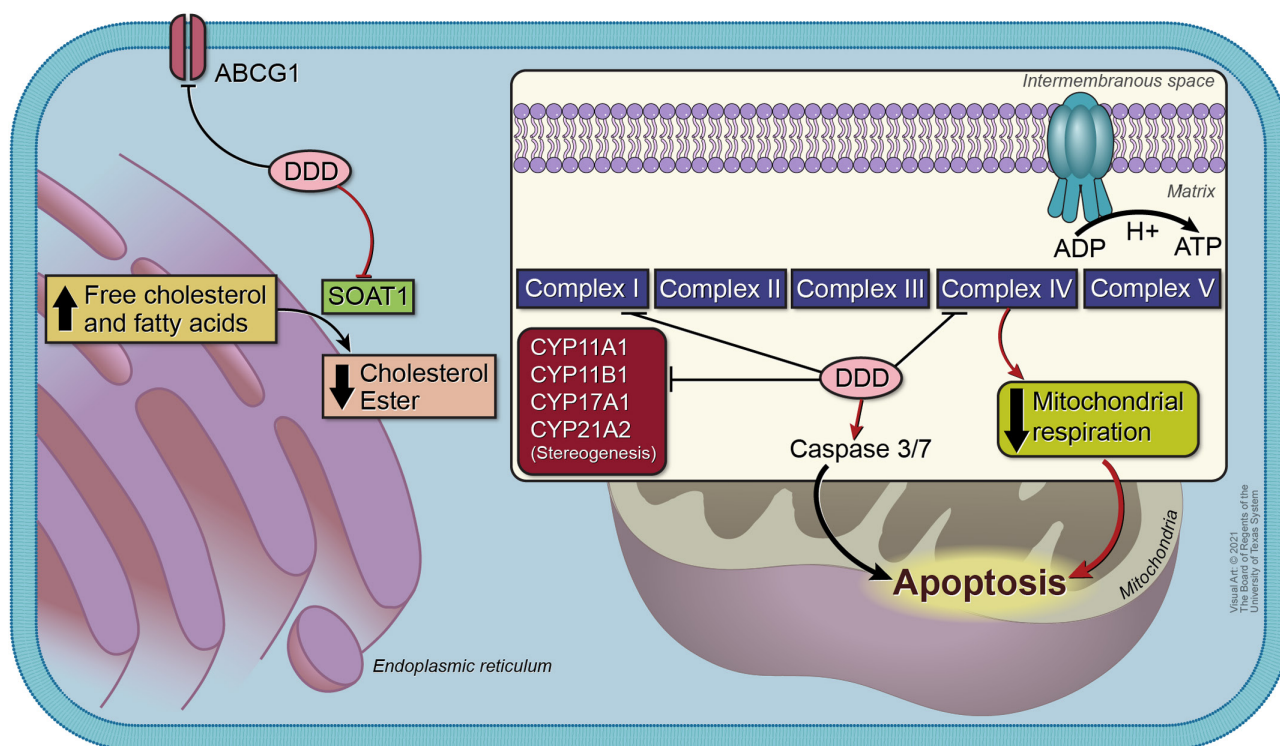
The first published retrospective study regarding the efficacy of adjuvant RT in patients with ACC was conducted in 2006. The study included 28 patients: 14 controls (surgery only) and 14 in the adjuvant treatment group. The 5-year probability of being free of local recurrence was 79% in the adjuvant RT group compared with 12% in the surgery-only group ($P=0.01$); however, OS did not differ much between the groups (Fassnacht *et al.* 2006). Later, a 2018 study of 1184 ACC patients in the National Cancer Database found that only 171 had received adjuvant RT (Nelson *et al.* 2018). Of those patients, adjuvant RT was associated with a 40% decreased risk of death (HR, 0.60; 95% CI, 0.40–0.92; $P=0.02$) in patients with positive surgical margins. Unfortunately, there was no clear benefit in older patients with a nodal-positive disease or high-grade histology. A recent meta-analysis of 6 studies with a total of 238 participants compared patients who received adjuvant RT with those who received surgery alone and found that adjuvant RT was associated with significantly higher OS (odds ratio, 2.27; 95% CI, 1.23–4.18; $P=0.009$). The etiologies related to the observed association between adjuvant RT and improved survival in a subset of ACC patients with positive margins remain unclear. Until we have future prospective studies to confirm if this association is true, we speculate that in some patients who will only develop local recurrence, RT may play a role in improving outcomes, while RT may have limited role in patients who develop distant and local recurrences.

On the other hand, another study using the National Cancer Database registry of 1557 patients with ACC compared adjuvant RT vs surgery alone in patients with a higher risk of recurrence using a propensity-matched analysis found worse median survival in patients receiving RT compared to those who underwent surgery alone (19.5 vs 22.8 months; $P=0.042$). Of note, patients who received RT in this study were more likely to have begun with incomplete resection and evidence of lymphovascular invasion. The authors concluded that RT does not confer a survival benefit when used as an adjuvant and recommended an individualized approach for adjuvant RT for ACC patients with high-risk features (Chen *et al.* 2021). Thus, further prospective studies are needed to fully understand the benefit of adjuvant RT in ACC.

Mitotane

Mitotane, the only antineoplastic drug used in the treatment of ACC, is a derivative compound of the insecticide dichloro-diphenyl-trichloroethane (DDT). Mitotane was first isolated from DDT in the 1940s. Its efficacy in treating ACC was first reported in 1959 in a case study (Bergental 1959). It was then introduced to the market in the 1960s (Corso *et al.* 2021). Although it has been more than 50 years since the introduction of mitotane in the clinic, its precise mechanism of action is still not fully known. Several mechanisms have been proposed (Fig. 1). These include (1) altering mitochondrial enzymes by covalently binding to cytochrome P450 enzymes (CPY11A1, CYP11B1, CYP17A1, and CYP21A2), which are involved in steroidogenesis causing altered hormonal concentrations; (2) reducing the expression of key proteins in steroidogenesis, such as STAR protein and sterol-O-acyl-transferase 1 (SOAT1), on the transcriptional level which was recently correlated with aggressive behavior (Sbiera *et al.* 2015, Lacombe *et al.* 2020); (3) inhibiting SOAT1, leading to the accumulation of free cholesterol and thus causing cell death (Lin *et al.* 2012); (4) interfering with the mitochondrial respiratory chain function complexes I (ubiquinone oxidoreductase) and IV (cytochrome c oxidase), leading to the induction of mitochondrial membrane fragmentation; (5) initiating the apoptotic process by activating caspase 3 and caspase 7 (Corso *et al.* 2021); and (6) strongly inducing CYP3A4 activity, leading to glucocorticoid inactivation and increased steroid clearance (Chortis *et al.* 2013). Recently, SOAT1 was studied retrospectively in ACC patients treated with adjuvant mitotane but there was no correlation between SOAT1 expression and key clinical endpoints such as RFS (Weigand *et al.* 2020). In a prospective phase I study, using a selective SOAT1 inhibitor (nevanimibe) in patients with metastatic ACC did not yield meaningful responses possibly because of the limitation in achieving therapeutic drug levels to affect ACC cell survival.

Although mitotane is approved for use in metastatic ACC, its use as adjuvant therapy is still based on expert opinion, retrospective data, and clinical practice guidelines, given the lack of prospective evidence for its efficacy. According to the 2018 ENSAT guidelines, its use is recommended in ACC patients with high-risk features (Fassnacht *et al.* 2018), and many expert cancer centers recommend its use in the adjuvant setting (Puglisi *et al.* 2020). Mitotane onset of action is often delayed, and it takes about 3 months for its blood concentration to reach the therapeutic target for metastatic ACC (14–20 mg/L) (Terzolo *et al.* 2013). For adjuvant therapy, the therapeutic



Visual Arts © 2021
University of Texas System

Figure 1

Mitotane's mechanism of action. ABCG1, ATP-binding cassette subfamily G member; complex I, ubiquinone oxidoreductase; complex II, succinate dehydrogenase; complex III, ubiquinol-cytochrome c oxidoreductase; complex IV, cytochrome c oxidase; complex V, ATP synthase; CYP11A1, cytochrome P450 family 11 subfamily A member 1; CYP17A1, cytochrome P450 family 17 subfamily A member 1; CYP21A2, cytochrome P450 family 21 subfamily A member 2; CYP11B1, cytochrome P450 family 11 subfamily B member; SOAT1, sterol O-acyltransferase.

target is still uncertain as the duration of treatment is needed to prevent disease recurrence (Puglisi *et al.* 2019).

Early, small studies on adjuvant mitotane, including a retrospective 1936–1987 study of 21 patients and a 2001 study of 11 patients, showed no significant benefit to patients (Bodie *et al.* 1989, Baudin *et al.* 2001). In contrast, a 1995 study of 26 patients and a 1998 study of 4 patients showed benefits (Kasperlik-Zaluška *et al.* 1995, Dickstein *et al.* 1998). It is difficult to interpret these studies as they lacked significant power, some involved multiple adjuvant therapies, different mitotane formulations, different doses, and few had matched control groups.

Larger, more recent studies have been supportive of adjuvant mitotane. A 2007 retrospective study of 177 patients in 8 Italian and 47 German centers used mitotane as adjuvant therapy after radical surgical resection performed between 1985 and 2005 and included a 10-year follow-up period (Terzolo *et al.* 2007). The median RFS was significantly longer in the mitotane group than in the Italian control group (42 months vs 10 months; HR, 3.79; 95% CI, 2.27–6.32; $P < 0.001$) and in the German control group (42 months vs 25 months; HR, 2.93; 95% CI, 1.74–4.940; $P = 0.005$) (Terzolo *et al.* 2007). This study was the

first to challenge the belief that mitotane was ineffective and prove that small mitotane doses (1–5 g/day) have a favorable effect (Terzolo *et al.* 2007, Grubbs *et al.* 2010).

In 2010, an MD Anderson Cancer Center retrospective study of 218 patients showed that the median DFS for those patients treated with mitotane was 30 months vs 12 months in patients without mitotane ($P = 0.05$) (Grubbs *et al.* 2010). Another study of 30 patients treated with adjuvant mitotane showed improvement in DFS in patients with complete resection (HR for recurrence, 0.58; 95% CI, 0.29–1.15; $P = 0.12$) (Fassnacht *et al.* 2010). A 2019 study of 152 patients (100 patients with and 52 without mitotane treatment) stratified the patients by disease stage (I–II vs III), hormone secretion levels, and Ki-67 percentage scores showed that the nontreated group had a higher risk of recurrence than the mitotane-treated group (HR, 2.79; 95% CI, 1.58–4.91; $P < 0.001$) (Calabrese *et al.* 2019). Two other meta-analyses also showed that adjuvant mitotane was associated with prolonged OS (first study: HR, 0.69; 95% CI, 0.55–0.88; $P < 0.01$ and second study: HR, 0.7; 95% CI, 0.5–0.9) and RFS (first study: HR, 0.62; 95% CI, 0.42–0.94; $P = 0.02$ and second study: HR, 0.7; 95% CI, 0.5–0.9) (Fassnacht *et al.* 2018, Tang *et al.* 2018).

ADIUVO study was the first trial to use mitotane in a randomized, controlled setting but mostly designed to evaluate patients deemed at low risk for recurrence. Patient criteria for inclusion included having stage I–III ACC, R0 surgery, and a Ki67 percentage score of 10% or less. A total of 91 patients were enrolled in the study (45 patients treated with adjuvant mitotane and 46 in the observational arm). RFS and OS did not differ significantly between the two groups, although, in the observational arm, the HR for recurrence was 1.321 (95% CI, 0.55–3.32; $P=0.54$) and the HR for death was 2.171 (95% CI, 0.52–12.12; $P=0.29$) (Terzolo *et al.* 2021).

A second prospective, randomized trial of adjuvant therapy, the ADIUVO-2 trial, was launched in August 2018 for patients who are deemed to be at high risk for recurrence. In this trial, the efficacy of mitotane vs mitotane plus cisplatin and etoposide in terms of DFS and OS is being studied as adjuvant therapies for preventing ACC recurrence (ClinicalTrials.gov identifier: NCT03583710).

Cytotoxic chemotherapy

Given the aggressive nature of ACC, over half of patients undergo relapse after complete surgical resection. Currently, mitotane is the most commonly used adjuvant therapy drug, and data supporting the use of cytotoxic chemotherapy are limited. As such, the European Society of Endocrinology

and European Society for Medical Oncology guidelines do not recommend standard adjuvant chemotherapy for patients with ACC but instead recommend case-by-case consideration based on the data available for systemic chemotherapy regimens (Fig. 2). Appropriate candidates for adjuvant chemotherapy are patients with a higher risk of relapse (i.e., those with one or more European Society of Endocrinology/European Society for Medical Oncology risk factors, including a Ki67 percentage score greater than 30%, a large tumor thrombus in the vena cava, stage IV disease, or R1 resection) (Fassnacht *et al.* 2020), as survival benefits have been demonstrated only for patients with locally advanced cancers (Al Asadi *et al.* 2021).

Although other solid malignancies have responded favorably to cytotoxic therapy, evidence for ACC remains limited for both adjuvant and palliative therapies. The FIRM-ACT trial of 2004–2010, which included 304 patients, was the first phase III randomized trial of chemotherapy in advanced or metastatic ACC, demonstrating that the platinum-based therapy (a combination of etoposide, doxorubicin, and cisplatin with mitotane) was superior to streptozocin plus mitotane (Fassnacht *et al.* 2020).

Recently, a retrospective multicenter cohort study of ACC in high-risk adults ($n=299$) demonstrated that patients who received adjuvant, platinum-based chemotherapy (cisplatin or carboplatin plus etoposide) had a 65% reduction in recurrence, improved OS, and longer PFS

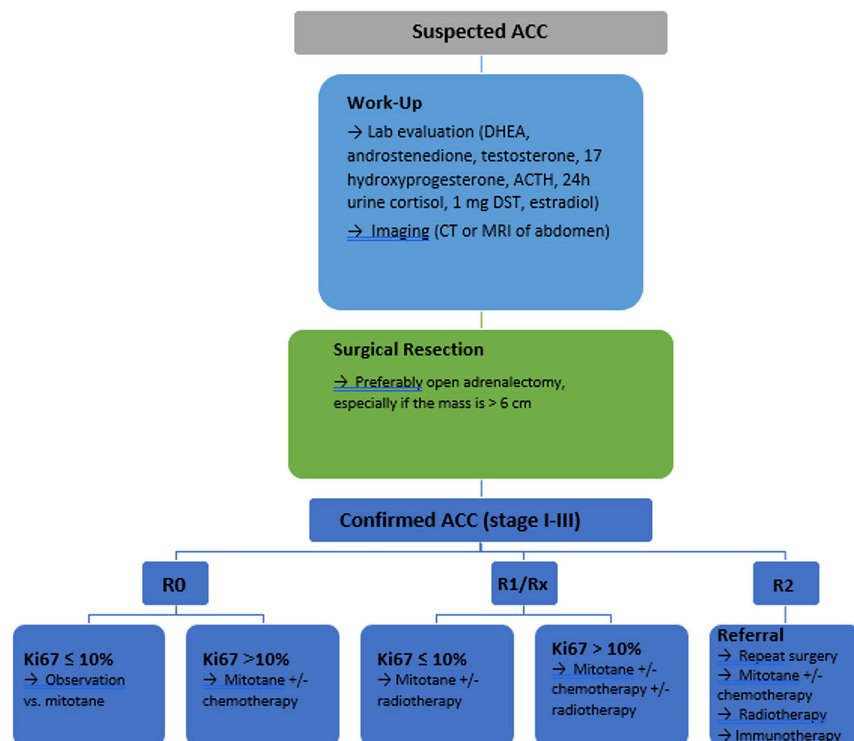


Figure 2

Suggested algorithm for the management of localized adrenocortical carcinoma. ACC, adrenocortical carcinoma; ACTH, adrenocorticotrophic hormone; DST, dexamethasone suppression test; R0, no evidence of tumor; R1, microscopic evidence of tumor; R2, macroscopic residual disease; RX, margins unknown.

(20.5 months vs 9.1 months; $P < 0.00$) compared with patients without adjuvant chemotherapy (Kimpel *et al.* 2021).

Considering the lack of prospective evidence for adjuvant chemotherapy in high-risk ACC, the ADIUVO2 trial (ClinicalTrials.gov identifier, NCT03583710) was established. In this phase III, randomized, pragmatic, clinical trial, there will be a comparison of outcomes between patients receiving 2 years of adjuvant mitotane alone vs patients receiving 2 years of mitotane in addition to 3 months of cisplatin and etoposide. This study aims to enroll 240 patients (120 patients in each arm) who have undergone primary surgical resection for localized ACC and have a high risk of recurrence (stage I–III disease and a Ki67 percentage score $>10\%$). The primary objective is RFS, and the secondary objectives include OS, clinical outcomes, adverse events, and quality of life.

Immunotherapy

Currently, research to determine immunotherapy targets for ACC is ongoing. It has focused primarily on salvage therapy for ACC tumors that have failed other treatments; to date, no study of immunotherapy as an adjuvant therapy has been performed (De Filipo *et al.* 2021). Monoclonal antibodies that successfully target the CTLA-4, PD1–PD-L1 pathway in other solid tumors have recently been used, as the PD-L1 pathway is used by cancer cells for immunosuppression of their environment and the promotion of tumor growth (Alsaab *et al.* 2017). However, although ACC tumors have some PD-L1 expression (Fay *et al.* 2015), clinical trials showed success in the minority of patients. Researchers have pointed out that responsiveness to checkpoint blockade immunotherapy requires CD8+ cells, which are downregulated in ACC because of T53 mutations and WNT- β -catenin amplifications, both of which impair CD8's action (Cosentini *et al.* 2018). Additionally, PD-L1 expression, although present in ACC, is lower than that in other cancers, and the glucocorticoid secretion level of some ACC tumors has an immunosuppressive effect that limits targeted therapy (Landwehr *et al.* 2020).

More recent studies have focused on pembrolizumab as salvage therapy, which also targets PD-1 and overall seems to be better tolerated. A literature review of four case series and four prospective studies (115 patients total) noted that pembrolizumab was well tolerated and associated with prolonged OS ranging from 4.3 to 31 months (Brabo *et al.* 2020).

While there is no robust data to compare the clinical outcomes of ACC patients treated with immune checkpoint inhibitors based on cortisol production, the preclinical

and translational data suggest that the cortisol effect could limit the benefit of immunotherapy (Landwehr *et al.* 2020, Greenstein *et al.* 2021). Thus, controlling cortisol excess in theory could enhance the response to immunotherapy. There is currently an ongoing trial phase 1b trial to investigate the efficacy of the combination of relacorilant (a selective glucocorticoid receptor inhibitor) with pembrolizumab in ACC (Clinical Trail Identifier: NCT04373265).

Future prospective studies are needed to determine the effectiveness of using immunotherapy in the adjuvant setting.

Conclusions

ACC is an aggressive cancer with a high risk of recurrence. The main factors predicting tumor recurrence are advanced disease, positive surgical margins, high Ki67 percentage scores, mitotic indices, hormonally active tumors, and certain genetic and cluster subtypes. Despite significant progress in developing adjuvant therapies for ACC, the field is still evolving, and studies sometimes present conflicting data. Much of the data on adjuvant therapy comes from retrospective studies of both adjuvant and salvage therapy in patients with ACC. Thus, strong data are lacking given the absence of formal prospective studies and randomized controlled trials. Future research should include more prospective studies, including those examining the use of genetic profiling, to validate the usefulness of the predictors of ACC recurrence. Results from future prospective clinical trials of adjuvant mitotane, chemotherapy, RT, and, especially, immunotherapy are also needed to better inform practicing physicians about the best approaches to reduce ACC recurrence via adjuvant therapy.

Declaration of interest

The authors declare that there is no conflict of interest that could be perceived as prejudicing the impartiality of this review.

Funding

This work was supported in part by the NIH/NCI under award number P30CA016672.

Author contribution statement

R A: Writing and editing the manuscript. C Z: Writing and editing the manuscript. M H: PI reviewing and editing the manuscript.

Acknowledgements

Editorial assistance was provided by Laura L Russell, The University of Texas MD Anderson Cancer Center Editing Services, Research Medical Library.

References

Al Asadi A, Hubbs DM, Sweigert PJ, Baker MS & Kabaker AS 2021 Analysis of adjuvant chemotherapy in patients undergoing curative-intent resection of localized adrenocortical carcinoma. *American Journal of Surgery* **222** 119–125. (<https://doi.org/10.1016/j.amjsurg.2020.10.038>)

Alsaab HO, Sau S, Alzhrani R, Tatiparti K, Bhise K, Kashaw SK & Iyer AK 2017 PD-1 and PD-L1 checkpoint signaling inhibition for cancer immunotherapy: mechanism, combinations, and clinical outcome. *Frontiers in Pharmacology* **8** 561. (<https://doi.org/10.3389/fphar.2017.00561>)

Amin MB, Greene FL, Edge SB, Compton CC, Gershenwald JE, Brookland RK, Meyer L, Gress DM, Byrd DR & Winchester DP 2017 The eighth edition AJCC cancer staging manual: continuing to build a bridge from a population-based to a more “personalized” approach to cancer staging. *CA: A Cancer Journal for Clinicians* **67** 93–99. (<https://doi.org/10.3322/caac.21388>)

Anderson KL, Adam MA, Thomas SM, Youngwirth L, Stang MT, Scheri RP, Roman SA & Sosa JA 2018 Impact of micro- and macroscopically positive surgical margins on survival after resection of adrenocortical carcinoma. *Annals of Surgical Oncology* **25** 1425–1431. (<https://doi.org/10.1245/s10434-018-6398-5>)

Angelousi A, Zilbermint M, Berthon A, Espiard S & Stratakis CA 2016 Diagnosis and management of hereditary adrenal cancer. In *Rare Hereditary Cancers*. Berlin, Germany: Springer.

Assié G, Jouinot A, Fassnacht M, Libé R, Garinet S, Jacob L, Hamzaoui N, Neou M, Sakat J, De La Villéon B, *et al.* 2019 Value of molecular classification for prognostic assessment of adrenocortical carcinoma. *JAMA Oncology* **5** 1440–1447. (<https://doi.org/10.1001/jamaoncol.2019.1558>)

Autorino R, Bove P, De Sio M, Miano R, Micali S, Cindolo L, Greco F, Nicholas J, Fiori C, Bianchi G, *et al.* 2016 Open versus laparoscopic adrenalectomy for adrenocortical carcinoma: a meta-analysis of surgical and oncological outcomes. *Annals of Surgical Oncology* **23** 1195–1202. (<https://doi.org/10.1245/s10434-015-4900-x>)

Ayabe RI, Narayan RR, Ruff SM, Wach MM, Lo W, Nierop PMH, Steinberg SM, Ripley RT, Davis JL, Koerkamp BG, *et al.* 2020 Disease-free interval and tumor functional status can be used to select patients for resection/ablation of liver metastases from adrenocortical carcinoma: insights from a multi-institutional study. *HPB* **22** 169–175. (<https://doi.org/10.1016/j.hpb.2019.07.002>)

Ayala-Ramirez M, Jasim S, Feng L, Ejaz S, Deniz F, Busaidy N, Waguespack SG, Naing A, Sircar K, Wood CG, *et al.* 2013 Adrenocortical carcinoma: clinical outcomes and prognosis of 330 patients at a tertiary care center. *European Journal of Endocrinology* **169** 891–899. (<https://doi.org/10.1530/EJE-13-0519>)

Baudin E, Pellegriti G, Bonnay M, Penfornis A, Laplanche A, Vassal G & Schlumberger M 2001 Impact of monitoring plasma 1, 1-dichlorodiphenildichloroethane (o, p' DDD) levels on the treatment of patients with adrenocortical carcinoma. *Cancer* **92** 1385–1392. ([https://doi.org/10.1002/1097-0142\(20010915\)92:6<1385::aid-cnrcr1461>3.0.co;2-2](https://doi.org/10.1002/1097-0142(20010915)92:6<1385::aid-cnrcr1461>3.0.co;2-2))

Bergental D 1959 Regression of adrenal cancer and suppression of adrenal function in man by o, p'DDD. *Transactions of the Association of American Physicians* **72** 341–350. (<https://doi.org/10.1016/B978-1-4832-2866-2.50035-0>)

Beuschlein F, Weigel J, Saeger W, Kroiss M, Wild V, Daffara F, Libé R, Ardito A, Al Ghuzlan A, Quinkler M, *et al.* 2015 Major prognostic role of Ki67 in localized adrenocortical carcinoma after complete resection. *Journal of Clinical Endocrinology and Metabolism* **100** 841–849. (<https://doi.org/10.1210/jc.2014-3182>)

Bilimoria KY, Shen WT, Elaraj D, Bentrem DJ, Winchester DJ, Kebebew E & Sturgeon C 2008 Adrenocortical carcinoma in the United States: treatment utilization and prognostic factors. *Cancer* **113** 3130–3136. (<https://doi.org/10.1002/cncr.23886>)

Bodie B, Novick AC, Pontes JE, Straffon RA, Montie JE, Babiak T, Sheeler L & Schumacher P 1989 The Cleveland Clinic experience with adrenal cortical carcinoma. *Journal of Urology* **141** 257–260. ([https://doi.org/10.1016/s0022-5347\(17\)40734-8](https://doi.org/10.1016/s0022-5347(17)40734-8))

Bolla M, Van Poppel H, Tombal B, Vekemans K, Da Pozzo L, De Reijke TM, Verbaeys A, Bosset JF, Van Velthoven R, Colombel M, *et al.* 2012 Postoperative radiotherapy after radical prostatectomy for high-risk prostate cancer: long-term results of a randomised controlled trial (EORTC trial 22911). *Lancet* **380** 2018–2027. ([https://doi.org/10.1016/S0140-6736\(12\)61253-7](https://doi.org/10.1016/S0140-6736(12)61253-7))

Brabo EP, Moraes AB & Neto LV 2020 The role of immune checkpoint inhibitor therapy in advanced adrenocortical carcinoma revisited: review of literature. *Journal of Endocrinological Investigation* **43** 1531–1542. (<https://doi.org/10.1007/s40618-020-01306-5>)

Calabrese A, Basile V, Puglisi S, Perotti P, Pia A, Saba L, Berchiolla P, Porpiglia F, Veltri A, Volante M, *et al.* 2019 Adjuvant mitotane therapy is beneficial in non-metastatic adrenocortical carcinoma at high risk of recurrence. *European Journal of Endocrinology* **180** 387–396. (<https://doi.org/10.1530/EJE-18-0923>)

Chen E, Kharouta MZ & Biswas T 2021 The role of adjuvant radiotherapy in non-metastatic adrenocortical carcinoma: analysis of a National Hospital-based registry. *International Journal of Radiation Oncology, Biology, Physics* **111** e261. (<https://doi.org/10.1016/j.ijrobp.2021.07.859>)

Chortis V, Taylor AE, Schneider P, Tomlinson JW, Hughes BA, O'Neil DM, Libé R, Allolio B, Bertagna X, Bertherat J, *et al.* 2013 Mitotane therapy in adrenocortical cancer induces CYP3A4 and inhibits 5 α -reductase, explaining the need for personalized glucocorticoid and androgen replacement. *Journal of Clinical Endocrinology and Metabolism* **98** 161–171. (<https://doi.org/10.1210/jc.2012-2851>)

Cooper AB, Habra MA, Grubbs EG, Bednarski BK, Ying AK, Perrier ND, Lee JE & Aloia TA 2013 Does laparoscopic adrenalectomy jeopardize oncologic outcomes for patients with adrenocortical carcinoma? *Surgical Endoscopy* **27** 4026–4032. (<https://doi.org/10.1007/s00464-013-3034-0>)

Corso CR, Acco A, Bach C, Bonatto SJR, De Figueiredo BC & De Souza LM 2021 Pharmacological profile and effects of mitotane in adrenocortical carcinoma. *British Journal of Clinical Pharmacology* **87** 2698–2710. (<https://doi.org/10.1111/bcp.14721>)

Cosentini D, Grisanti S, Dalla Volta A, Laganà M, Fiorentini C, Perotti P, Sigala S & Berruti A 2018 Immunotherapy failure in adrenocortical cancer: where next? *Endocrine Connections* **7** E5–E8. (<https://doi.org/10.1530/EC-18-0398>)

De Filpo G, Mannelli M & Canu L 2021 Adrenocortical carcinoma: current treatment options. *Current Opinion in Oncology* **33** 16–22. (<https://doi.org/10.1097/CCO.0000000000000695>)

Dickstein G, Shechner C, Arad E, Best LA & Nativ O 1998 Is there a role for low doses of mitotane (o, p' DDD) as adjuvant therapy in adrenocortical carcinoma? *Journal of Clinical Endocrinology and Metabolism* **83** 3100–3103. (<https://doi.org/10.1210/jcem.83.9.5113>)

Duregon E, Molinaro L, Volante M, Ventura L, Righi L, Bolla S, Terzolo M, Sapino A & Papotti MG 2014 Comparative diagnostic and prognostic performances of the hematoxylin-eosin and phospho-histone H3 mitotic count and Ki-67 index in adrenocortical carcinoma. *Modern Pathology* **27** 1246–1254. (<https://doi.org/10.1038/modpathol.2013.230>)

Early Breast Cancer Trialists' Collaborative Group (EBCTCG), Darby S, McGale P, Correa C, Taylor C, Arriagada R, Clarke M, Cutter D, Davies C, Ewertz M, *et al.* 2011 Effect of radiotherapy after breast-conserving surgery on 10-year recurrence and 15-year breast cancer death: meta-analysis of individual patient data for 10 801 women in 17 randomised trials. *Lancet* **378** 1707–1716. ([https://doi.org/10.1016/S0140-6736\(11\)61629-2](https://doi.org/10.1016/S0140-6736(11)61629-2))

Elhassan YS, Altieri B, Berhane S, Cosentini D, Calabrese A, Haissaguerre M, Kastelan D, Frago MCBV, Bertherat J, Al Ghuzlan A, *et al.* 2021 S-GRAS score for prognostic classification of adrenocortical carcinoma: an international, multicenter ENSAT study. *European Journal of Endocrinology* **186** 25–36. (<https://doi.org/10.1530/EJE-21-0510>)

- Else T, Kim AC, Sabolch A, Raymond VM, Kandathil A, Caoili EM, Jolly S, Miller BS, Giordano TJ & Hammer GD 2014a Adrenocortical carcinoma. *Endocrine Reviews* **35** 282–326. (<https://doi.org/10.1210/er.2013-1029>)
- Else T, Williams AR, Sabolch A, Jolly S, Miller BS & Hammer GD 2014b Adjuvant therapies and patient and tumor characteristics associated with survival of adult patients with adrenocortical carcinoma. *Journal of Clinical Endocrinology and Metabolism* **99** 455–461. (<https://doi.org/10.1210/jc.2013-2856>)
- Fassnacht M, Hahner S, Polat B, Koschker AC, Kenn W, Flentje M & Allolio B 2006 Efficacy of adjuvant radiotherapy of the tumor bed on local recurrence of adrenocortical carcinoma. *Journal of Clinical Endocrinology and Metabolism* **91** 4501–4504. (<https://doi.org/10.1210/jc.2006-1007>)
- Fassnacht M, Johanssen S, Quinkler M, Bucszy P, Willenberg HS, Beuschlein F, Terzolo M, Mueller HH, Hahner S, Allolio B, *et al.* 2009 Limited prognostic value of the 2004 International Union Against Cancer staging classification for adrenocortical carcinoma: proposal for a revised TNM Classification. *Cancer* **115** 243–250. (<https://doi.org/10.1002/cncr.24030>)
- Fassnacht M, Johanssen S, Fenske W, Weismann D, Agha A, Beuschlein F, Fuhrer D, Jurowich C, Quinkler M, Petersenn S, *et al.* 2010 Improved survival in patients with stage II adrenocortical carcinoma followed up prospectively by specialized centers. *Journal of Clinical Endocrinology and Metabolism* **95** 4925–4932. (<https://doi.org/10.1210/jc.2010-0803>)
- Fassnacht M, Dekkers OM, Else T, Baudin E, Berruti A, De Krijger RR, Haak HR, Mihai R, Assie G & Terzolo M 2018 European Society of Endocrinology Clinical Practice Guidelines on the management of adrenocortical carcinoma in adults, in collaboration with the European Network for the Study of Adrenal Tumors. *European Journal of Endocrinology* **179** G1–G46. (<https://doi.org/10.1530/EJE-18-0608>)
- Fassnacht M, Assie G, Baudin E, Eisenhofer G, De La Fouchardiere C, Haak HR, De Krijger R, Porpiglia F, Terzolo M, Berruti A, *et al.* 2020 Adrenocortical carcinomas and malignant pheochromocytomas: ESMO–EURACAN Clinical Practice Guidelines for diagnosis, treatment and follow-up. *Annals of Oncology* **31** 1476–1490. (<https://doi.org/10.1016/j.annonc.2020.08.2099>)
- Fay AP, Signoretti S, Callea M, Telé GH, Mckay RR, Song J, Carvo I, Lampron ME, Kaymakalan MD, Poli-de-Figueiredo CE, *et al.* 2015 Programmed death ligand-1 expression in adrenocortical carcinoma: an exploratory biomarker study. *Journal for ImmunoTherapy of Cancer* **3** 3. (<https://doi.org/10.1186/s40425-015-0047-3>)
- Fragoso MCBV, Almeida MQ, Mazzuco TL, Mariani BMP, Brito LP, Gonçalves TC, Alencar GA, Lima Lde O, Faria AM, Bourdeau I, *et al.* 2012 Combined expression of BUB1B, DLGAP5, and PINK1 as predictors of poor outcome in adrenocortical tumors: validation in a Brazilian cohort of adult and pediatric patients. *European Journal of Endocrinology* **166** 61–67. (<https://doi.org/10.1530/EJE-11-0806>)
- Glenn JA, Else T, Hughes DT, Cohen MS, Jolly S, Giordano TJ, Worden FP, Gauger PG, Hammer GD & Miller BS 2019 Longitudinal patterns of recurrence in patients with adrenocortical carcinoma. *Surgery* **165** 186–195. (<https://doi.org/10.1016/j.surg.2018.04.068>)
- Greenstein AE, Habra MA, Wadekar SA & Grauer A 2021 Adrenal tumors provide insight into the role of cortisol in NK cell activity. *Endocrine-Related Cancer* **28** 583–592. (<https://doi.org/10.1530/ERC-21-0048>)
- Grubbs EG, Callender GG, Xing Y, Perrier ND, Evans DB, Phan AT & Lee JE 2010 Recurrence of adrenal cortical carcinoma following resection: surgery alone can achieve results equal to surgery plus mitotane. *Annals of Surgical Oncology* **17** 263–270. (<https://doi.org/10.1245/s10434-009-0716-x>)
- Heiss N, Rousson V, Ifticene-Treboux A, Lehr HA & Delaloye JF 2017 Risk factors for positive resection margins of breast cancer tumorectomy specimen following breast-conserving surgery. *Hormone Molecular Biology and Clinical Investigation* **32** [epub]. (<https://doi.org/10.1515/hmbci-2017-0023>)
- Jasim S & Habra MA 2019 Management of adrenocortical carcinoma. *Current Oncology Reports* **21** 20. (<https://doi.org/10.1007/s11912-019-0773-7>)
- Kasperlik-Zaluška AA, Migdalska BM, Zgliczyński S & Makowska AM 1995 Adrenocortical carcinoma. A clinical study and treatment results of 52 patients. *Cancer* **75** 2587–2591. ([https://doi.org/10.1002/1097-0142\(19950515\)75:10<2587::aid-cncr2820751028>3.0.co;2-5](https://doi.org/10.1002/1097-0142(19950515)75:10<2587::aid-cncr2820751028>3.0.co;2-5))
- Kerkhofs TM, Verhoeven RH, Van Der Zwan JM, Dieleman J, Kerstens MN, Links TP, Van De Poll-Franse LV & Haak HR 2013 Adrenocortical carcinoma: a population-based study on incidence and survival in the Netherlands since 1993. *European Journal of Cancer* **49** 2579–2586. (<https://doi.org/10.1016/j.ejca.2013.02.034>)
- Kimpel O, Bedrose S, Megerle F, Berruti A, Terzolo M, Kroiss M, Mai K, Dekkers OM, Habra MA & Fassnacht M 2021 Adjuvant platinum-based chemotherapy in radically resected adrenocortical carcinoma: a cohort study. *British Journal of Cancer* **125** 1233–1238. (<https://doi.org/10.1038/s41416-021-01513-8>)
- Lacombe AMF, Soares IC, Mariani BMP, Nishi MY, Bezerra-Neto JE, Charchar HDS, Brondani VB, Tanno F, Srougi V, Chambo JL, *et al.* 2020 Sterol O-acyl transferase 1 as a prognostic marker of adrenocortical carcinoma. *Cancers* **12** 247. (<https://doi.org/10.3390/cancers121010247>)
- Landwehr LS, Altieri B, Schreiner J, Sbierra I, Weigand I, Kroiss M, Fassnacht M & Sbierra S 2020 Interplay between glucocorticoids and tumor-infiltrating lymphocytes on the prognosis of adrenocortical carcinoma. *Journal for ImmunoTherapy of Cancer* **8** e000469. (<https://doi.org/10.1136/jitc-2019-000469>)
- Langenhuijsen J, Birtle A, Klatter T, Porpiglia F & Timsit MO 2016 Surgical management of adrenocortical carcinoma: impact of laparoscopic approach, lymphadenectomy, and surgical volume on outcomes – a systematic review and meta-analysis of the current literature. *European Urology Focus* **1** 241–250. (<https://doi.org/10.1016/j.euf.2015.12.001>)
- Liang J, Liu Z, Zhou L, Tang Y, Zhou C, Wu K, Zhang F, Zhang F, Wei X, Lu Y, *et al.* 2020 The clinical utility of ‘GRAS’ aparameters in stage I–III adrenocortical carcinomas: long-term data from a high-volume institution. *Endocrine* **67** 449–456. (<https://doi.org/10.1007/s12020-019-02141-2>)
- Lin CW, Chang YH & Pu HF 2012 Mitotane exhibits dual effects on steroidogenic enzymes gene transcription under basal and cAMP-stimulating microenvironments in NCI-H295 cells. *Toxicology* **298** 14–23. (<https://doi.org/10.1016/j.tox.2012.04.007>)
- Margonis GA, Amini N, Kim Y, Tran TB, Postlewait LM, Maithe SK, Wang TS, Evans DB, Hatzaras I, Shenoy R, *et al.* 2016a Incidence of perioperative complications following resection of adrenocortical carcinoma and its association with long-term survival. *World Journal of Surgery* **40** 706–714. (<https://doi.org/10.1007/s00268-015-3307-y>)
- Margonis GA, Kim Y, Prescott JD, Tran TB, Postlewait LM, Maithe SK, Wang TS, Evans DB, Hatzaras I, Shenoy R, *et al.* 2016b Adrenocortical carcinoma: impact of surgical margin status on long-term outcomes. *Annals of Surgical Oncology* **23** 134–141. (<https://doi.org/10.1245/s10434-015-4803-x>)
- Martins-Filho SN, Almeida MQ, Soares I, Wakamatsu A, Alves VAF, Fragoso MCBV & Zerbini MCN 2021 Clinical impact of pathological features including the Ki-67 labeling index on diagnosis and prognosis of adult and pediatric adrenocortical tumors. *Endocrine Pathology* **32** 288–300. (<https://doi.org/10.1007/s12022-020-09654-x>)
- Masuda N, Lee SJ, Ohtani S, Im YH, Lee ES, Yokota I, Kuroi K, Im SA, Park BW, Kim SB, *et al.* 2017 Adjuvant capecitabine for breast cancer after preoperative chemotherapy. *New England Journal of Medicine* **376** 2147–2159. (<https://doi.org/10.1056/NEJMoa1612645>)
- Miller BS, Gauger PG, Hammer GD, Giordano TJ & Doherty GM 2010 Proposal for modification of the ENSAT staging system for adrenocortical carcinoma using tumor grade. *Langenbeck's Archives of Surgery* **395** 955–961. (<https://doi.org/10.1007/s00423-010-0698-y>)
- Mohan DR, Lerario AM, Else T, Mukherjee B, Almeida MQ, Vinco M, Rege J, Mariani BMP, Zerbini MCN, Mendonca BB, *et al.* 2019 Targeted assessment of GOS2 methylation identifies a rapidly recurrent, routinely fatal molecular subtype of adrenocortical carcinoma. *Clinical Cancer Research* **25** 3276–3288. (<https://doi.org/10.1158/1078-0432.CCR-18-2693>)

- Mpaili E, Moris D, Tsimimigras DI, Oikonomou D, Pawlik TM, Schizas D, Papalampros A, Felekouras E & Dimitroulis D 2018 Laparoscopic versus open adrenalectomy for localized/locally advanced primary adrenocortical carcinoma (ENSAT I-III) in adults: is margin-free resection the key surgical factor that dictates outcome? A review of the literature. *Journal of Laparoscopic and Advanced Surgical Techniques: Part A* **28** 408–414. (<https://doi.org/10.1089/lap.2017.0546>)
- Nelson DW, Chang SC, Bandera BC, Fischer TD, Wollman R & Goldfarb M 2018 Adjuvant radiation is associated with improved survival for select patients with non-metastatic adrenocortical carcinoma. *Annals of Surgical Oncology* **25** 2060–2066. (<https://doi.org/10.1245/s10434-018-6510-x>)
- Nowak KM, Samsel R, Cichocki A, Ambroziak U, Roszkowska-Purska K, Łebek-Szatańska A, Koperski Ł, Otto M, Zgliczyński W & Papierska L 2018 Prognostic factors in adrenocortical carcinoma: data from a large Polish series. *Polish Archives of Internal Medicine* **128** 371–378. (<https://doi.org/10.20452/pamw.4260>)
- Pennanen M, Heiskanen I, Sane T, Remes S, Mustonen H, Haglund C & Arola J 2015 Helsinki score – a novel model for prediction of metastases in adrenocortical carcinomas. *Human Pathology* **46** 404–410. (<https://doi.org/10.1016/j.humpath.2014.11.015>)
- Puglisi S, Calabrese A, Basile V, Ceccato F, Scaroni C, Simeoli C, Torlontano M, Cannavò S, Arnaldi G, Stigliano A, *et al.* 2019 Mitotane concentrations influence the risk of recurrence in adrenocortical carcinoma patients on adjuvant treatment. *Journal of Clinical Medicine* **8** 1850. (<https://doi.org/10.3390/jcm8111850>)
- Puglisi S, Calabrese A, Basile V, Pia A, Reimondo G, Perotti P & Terzolo M 2020 New perspectives for mitotane treatment of adrenocortical carcinoma. *Best Practice and Research: Clinical Endocrinology and Metabolism* **34** 101415. (<https://doi.org/10.1016/j.beem.2020.101415>)
- Ramsay O 1899 Malignant tumors of the suprarenal glands. *Bulletin of the Johns Hopkins Hospital* **94** 96.
- Riedmeier M, Decarolis B, Haubitz I, Müller S, Uttinger K, Börner K, Reibetanz J, Wiegering A, Härtel C, Schlegel PG, *et al.* 2021 Adrenocortical carcinoma in childhood: a systematic review. *Cancers* **13** 5266. (<https://doi.org/10.3390/cancers13215266>)
- Sbiera S, Leich E, Liebisch G, Sbiera I, Schirbel A, Wiemer L, Matysik S, Eckhardt C, Gardill F, Gehl A, *et al.* 2015 Mitotane inhibits sterol-O-acyl transferase 1 triggering lipid-mediated endoplasmic reticulum stress and apoptosis in adrenocortical carcinoma cells. *Endocrinology* **156** 3895–3908. (<https://doi.org/10.1210/en.2015-1367>)
- Sbiera S, Sbiera I, Ruggiero C, Doghman-Bouguerra M, Korpershoek E, De Krijger RR, Eттаieb H, Haak H, Volante M, Papotti M, *et al.* 2017 Assessment of VAV2 expression refines prognostic prediction in adrenocortical carcinoma. *Journal of Clinical Endocrinology and Metabolism* **102** 3491–3498. (<https://doi.org/10.1210/jc.2017-00984>)
- Sgourakis G, Lanitis S, Kouloura A, Zaphiriadou P, Karkoulas K, Raptis D, Anagnostara A & Caraliotas C 2015 Laparoscopic versus open adrenalectomy for stage I/II adrenocortical carcinoma: meta-analysis of outcomes. *Journal of Investigative Surgery* **28** 145–152. (<https://doi.org/10.3109/08941939.2014.987886>)
- Tang Y, Liu Z, Zou Z, Liang J, Lu Y & Zhu Y 2018 Benefits of adjuvant mitotane after resection of adrenocortical carcinoma: a systematic review and meta-analysis. *BioMed Research International* **2018** 9362108. (<https://doi.org/10.1155/2018/9362108>)
- Terzolo M, Angeli A, Fassnacht M, Daffara F, Tauchmanova L, Conton PA, Rossetto R, Buci L, Sperone P, Grossrubatscher E, *et al.* 2007 Adjuvant mitotane treatment for adrenocortical carcinoma. *New England Journal of Medicine* **356** 2372–2380. (<https://doi.org/10.1056/NEJMoa063360>)
- Terzolo M, Baudin AE, Ardito A, Kroiss M, Leboulleux S, Daffara F, Perotti P, Feelders RA, Devries JH, Zaggia B, *et al.* 2013 Mitotane levels predict the outcome of patients with adrenocortical carcinoma treated adjuvantly following radical resection. *European Journal of Endocrinology* **169** 263–270. (<https://doi.org/10.1530/EJE-13-0242>)
- Terzolo M, Fassnacht M, Perotti P, Libe R, Lacroix A, Kastelan D, Haak HR, Arlt W, Loli P, Decoudier B, *et al.* 2021 Results of the ADIUVO study, the first randomized trial on adjuvant mitotane in adrenocortical carcinoma patients. *Journal of the Endocrine Society* **5** A166–A167. (<https://doi.org/10.1210/jendso/bvab048.336>)
- Thompson IM, Tangen CM, Paradelo J, Lucia MS, Miller G, Troyer D, Messing E, Forman J, Chin J, Swanson G, *et al.* 2006 Adjuvant radiotherapy for pathologically advanced prostate cancer: a randomized clinical trial. *JAMA* **296** 2329–2335. (<https://doi.org/10.1001/jama.296.19.2329>)
- Thoraeus R 1932 *A Study of the Ionization Method for Measuring the Intensity and Absorption of Roentgen Rays and of the Efficiency of Different Filters Used in Therapy*. Stockholm, Sweden: F. Englund.
- Tran TB, Maithele SK, Pawlik TM, Wang TS, Hatzaras I, Phay JE, Fields RC, Weber SM, Sicklick JK, Yopp AC, *et al.* 2016 Clinical score predicting long-term survival after repeat resection for recurrent adrenocortical carcinoma. *Journal of the American College of Surgeons* **223** 794–803. (<https://doi.org/10.1016/j.jamcollsurg.2016.08.568>)
- Turco M, Huguet J, Territo A, Fontana M, Rodriguez Faba O, Palou J & Breda A 2021 Outcomes following surgical management of adrenocortical carcinoma: a single-center experience. *Archivos Espanoles de Urologia* **74** 782–789. (<https://doi.org/10.37554/en-20210206-3424-8>)
- Vanbrabant T, Fassnacht M, Assie G & Dekkers OM 2018 Influence of hormonal functional status on survival in adrenocortical carcinoma: systematic review and meta-analysis. *European Journal of Endocrinology* **179** 429–436. (<https://doi.org/10.1530/EJE-18-0450>)
- Weigand I, Altieri B, Lacombe AMF, Basile V, Kircher S, Landwehr LS, Schreiner J, Zerbini MCN, Ronchi CL, Megerle F, *et al.* 2020 Expression of SOAT1 in adrenocortical carcinoma and response to mitotane monotherapy: an ENSAT multicenter study. *Journal of Clinical Endocrinology and Metabolism* **105** 2642–2653. (<https://doi.org/10.1210/clinem/dgaa293>)
- Zhang L, Wu B, Zha Z, Zhao H, Jiang Y & Yuan J 2018 Positive surgical margin is associated with biochemical recurrence risk following radical prostatectomy: a meta-analysis from high-quality retrospective cohort studies. *World Journal of Surgical Oncology* **16** 124. (<https://doi.org/10.1186/s12957-018-1433-3>)
- Zheng S, Cherniack AD, Dewal N, Moffitt RA, Danilova L, Murray BA, Lerario AM, Else T, Knijnenburg TA, Ciriello G, *et al.* 2016 Comprehensive pan-genomic characterization of adrenocortical carcinoma. *Cancer Cell* **29** 723–736. (<https://doi.org/10.1016/j.ccell.2016.04.002>)
- Zheng GY, Li HZ, Deng JH, Zhang XB & Wu XC 2018 Open adrenalectomy versus laparoscopic adrenalectomy for adrenocortical carcinoma: a retrospective comparative study on short-term oncologic prognosis. *Oncotargets and Therapy* **11** 1625–1632. (<https://doi.org/10.2147/OTT.S157518>)

Received in final form 20 June 2022

Accepted 26 July 2022

Accepted Manuscript published online 26 July 2022